


Posterior Cruciate Ligament Reconstruction Technique Using the
Modular ACL/PCL Guide
Rationale and Surgical Technique by Timothy Deakon, M.D.



ARTHROTEK[®]
A BIOMET COMPANY

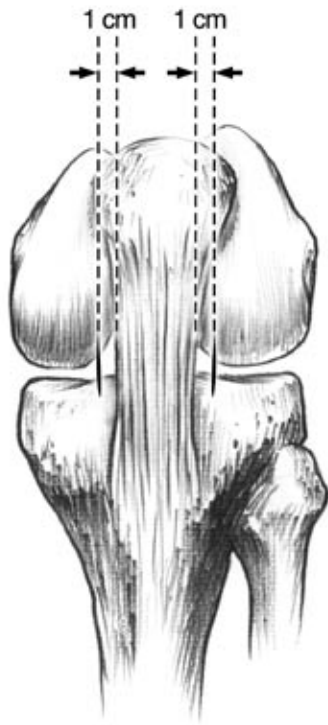


Figure 1

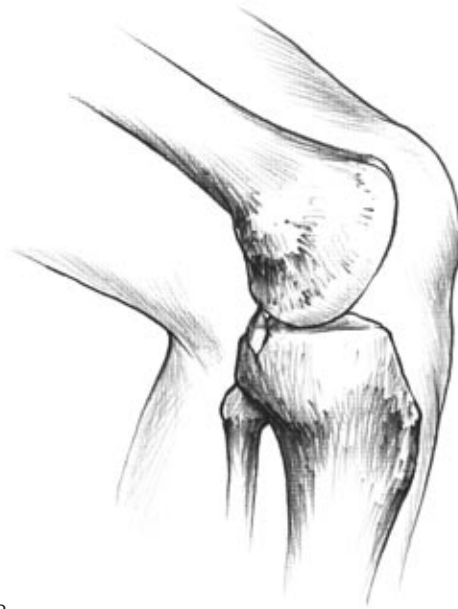

Figure 2

Begin the operation with examination under anesthesia to confirm whether there are any ligamentous instabilities in addition to the posterior cruciate ligament insufficiency. In particular it is important to determine if posterolateral instability (PLI) exists. If PLI is present, then it will need to be corrected along with the posterior cruciate ligament deficiency.

Portal Placement

Arthroscopy is initiated through anterolateral and anteromedial portals. The anterolateral portal is placed in a standard fashion 1cm lateral to the patellar ligament and 1cm inferior to the patella. The medial portal is placed in a high position 0.5 to 1cm medial to the patellar ligament and approximately 0.5 to 1cm inferior to the patella (Figure 1). This facilitates clearing of the posterior tibial insertion of the posterior cruciate ligament and facilitates placement of the Modular PCL guide.

Arthroscopy can then proceed with the standard examination of the patellofemoral compartment, the medial and lateral gutters, the medial compartment and lateral compartments. Intra-articular pathology is addressed at this point. Attention is then turned to the intercondylar area where the posterior cruciate insufficiency is confirmed.

It may be necessary to create a posterolateral portal or posteromedial portal to confirm the posterior cruciate ligament insufficiency. A posteromedial portal is normally used in the posterior cruciate

ligament reconstruction (Figure 2). This portal is created using an 18 gauge spinal needle. The arthroscope is placed through the intercondylar notch and into the posteromedial compartment of the knee to visualize the needle.

Once the portal position has been confirmed, a skin incision is created and the portal is established bluntly using mosquito forceps to prevent injury to the saphenous vein and nerve. A switching stick is then introduced and an arthroscopic cannula is placed over the switching stick. A tight fit of this arthroscopic cannula prevents extravasation of fluid and prevents damage to the saphenous vein and nerve with repetitive introduction of instruments through the posteromedial portal. Once the deficiency of the posterior cruciate ligament has been confirmed, the surgeon should proceed to remove only as much of the posterior cruciate ligament as is necessary to visualize the insertion points into the medial femoral condyle and the posterior tibia.

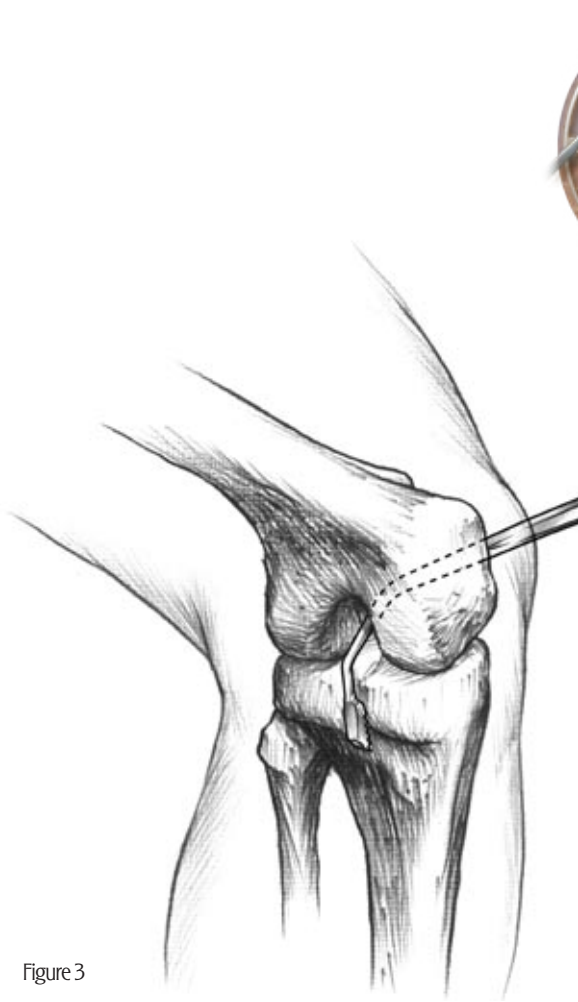


Figure 3



Figure 4

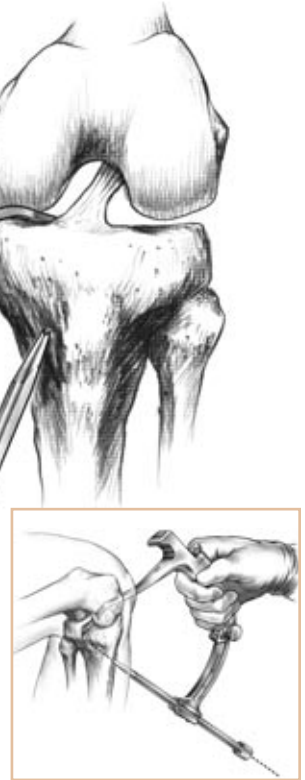

Figure 5

Tibial Tunnel Preparation

It is important to be able to visualize the tibial insertion of the posterior cruciate ligament down to the inferior insertion of the posterior knee capsule. The removal of this tissue can be facilitated by using the arthroscopic angled Cobb and curette hand instruments. (Figure 3). A shaver blade can be used through the posteromedial portal to remove the soft tissue along the posterior tibia down to the insertion of the capsule inferiorly. It is important not to breach the capsular insertion initially as this causes extravasation of fluid down into the calf.

Care must be taken during the removal of the posterior cruciate ligament to avoid damage to the anterior cruciate ligament and the posterior vessels.

Insertion of the Guide

Once the soft tissue has been cleared adequately, the Modular Guide, with the appropriate PCL arm attached, is introduced through the medial portal and advanced through the intercondylar notch. It is then seated on the posterior tibia (Figure 4). A 10mm medial portal should be sufficient to introduce the guide. If difficulty is encountered introducing the guide it can be inserted upside down and then rotated around through the intercondylar notch and down along the posterior cortex of the tibia.

The desired position for the tibial tunnel is 10 to 12mm below the posterior horn insertion of the lateral meniscus and 5 to 10mm lateral to the midline of the knee (Figure 5). This position can be confirmed with fluoroscopy intraoperatively. In most cases, the guide wire for the tibial tunnel will arise just superior to the capsular insertion of the posterior knee capsule while viewed from the posteromedial portal. The correct positioning of the guide should be confirmed with the arthroscope in the posteromedial portal position. The standard 30° arthroscope should be sufficient for this purpose.

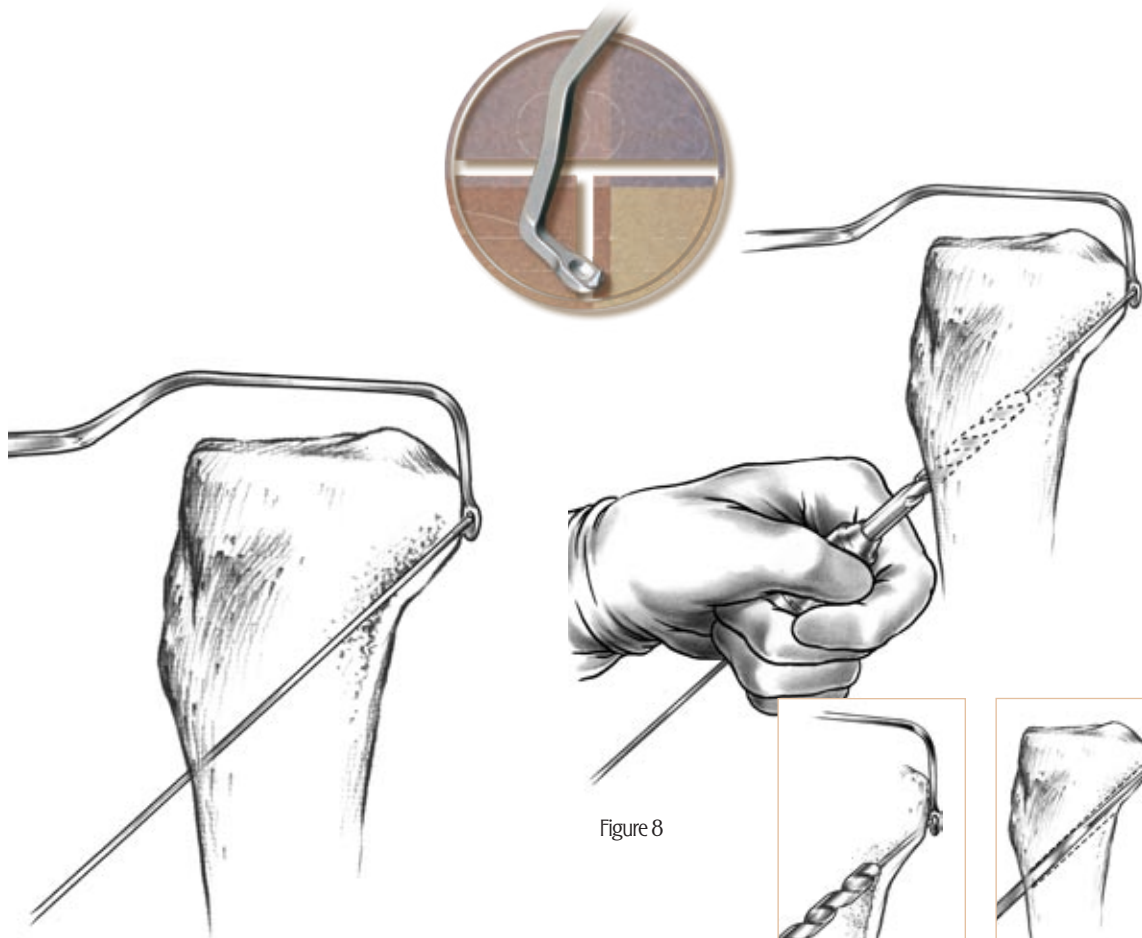


Figure 6

Figure 8

Figure 7

Figure 9

Drilling the Tibial Guide Wire

The guide sleeve is then moved into place. A skin incision is made 1.5cm medial and 1cm inferior to the tibial tubercle. Subperiosteal dissection of the bone is performed and the guide wire is advanced until it reaches the posterior cortex of the tibia. The tibial guide is removed and the wire tip protector inserted.

The posterior structures (tibial vessels and nerve) are protected by the spoon shaped protector on the intra-articular portion of the Modular PCL guide (Figure 6). Tibial wire positioning should be confirmed intraoperatively using either fluoroscopy or X-ray. The desired position is the lower one-third of the posterior tibial slope in the lateral X-ray view and just lateral to the midline in the AP view (0.5 to 1cm).

Completion of Tibial Tunnel

The drill bit is advanced over the wire until the posterior cortex is felt. The last few turns can either be made by hand or by carefully advancing the drill by power (Figure 7). If the drill breaks the posterior cortex, the remaining drilling should be done by turning the drill bit by hand (Figure 8).

The posterior edges of the tibial drill hole should be well radiused (Figure 9). This can be accomplished with the curved rasp up through the tibial tunnel or by using a burr in the posteromedial portal under direct visualization with the arthroscope.

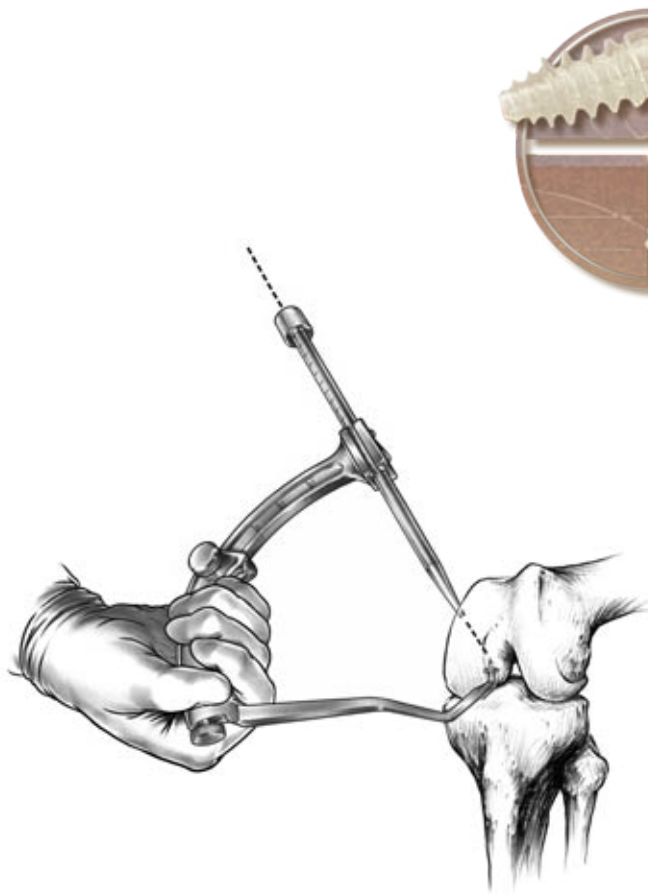


Figure 10

Drilling the Femoral Tunnel

The next step involves creating the femoral tunnel. This is best accomplished using the ACL arm for the tibial guide. The guide is placed through the medial portal. The tip of the guide should be placed in the superior anterior footprint of the native PCL roughly 8mm down from the top of the intercondylar notch, and 8 to 10mm posterior to the articular cartilage margin (Figure 10). The guide wire should be inserted using an outside-in technique.

The desired external position for the femoral tunnel is a point midway between the medial epicondyle and the medial border of the patella 1 to 2cm superior to the medial epicondyle. The interarticular edges of the drill hole should be well radiused.

An alternative method to create the femoral tunnel uses an inferolateral/anterolateral portal. This portal is located just above the anterior edge of the lateral meniscus. A wire is drilled through this portal, and through the desired femoral origin point of the posterior cruciate ligament.

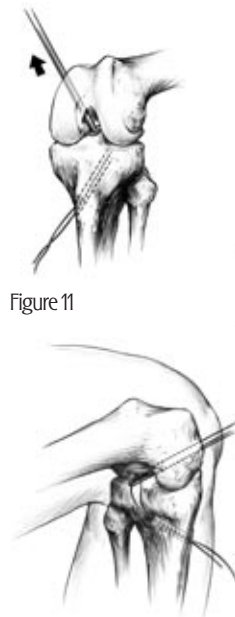


Figure 11

Figure 12

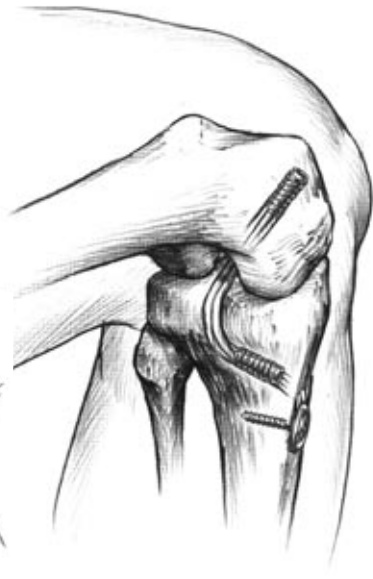

Figure 13

Graft Passage

A looped wire is passed up the tibial tunnel and into the intercondylar notch. A grasping instrument is placed through the femoral tunnel and the wire loop is grasped (Figures 11 & 12). The graft is then advanced from the tibial tunnel up into the femoral tunnel when using bone patellar ligament bone, or alternatively through the femoral tunnel into the tibial tunnel when using Achilles tendon allograft or hamstring tendon. Sterile mucin can be used to facilitate the passage of the graft in cases of a tight tunnel graft matching.

Fixation of the Graft

If the patient also has a posterolateral instability that needs to be reconstructed, it is performed at this time in the surgical procedure. When the posterolateral reconstruction is completed, attention is then turned back to the anterior aspect of the knee for fixation. Traction is placed on the PCL graft sutures distally and tension is applied. The knee is then cycled through 25 full flexion and extension cycles to allow settling of the graft. The knee is then returned to 70 to 90° of flexion. An anterior drawer force is applied to restore the normal tibial stepoffs and traction is placed on the PCL graft. Next, fixation may be achieved with interference screws, screws and washers, or a combination of the two depending on the graft and the surgeon's preference (Figure 13).



Ordering Information

Modular Guide Body w/ ACL Arm

909505

PCL Arm

909503 Left Arm
909504 Right Arm

PCL Rasp

909890

PCL Straight Curette

909891

PCL Curved Curette

909892

PCL Wire Protector

909893

³/₃₂" Modular Guide Wire

909894

Looped Suture Wire

909807

³/₃₂" Graft Passing Pin

909640

3.5mm Hex Screwdriver

906846

Graft Sizing Block

906820

Femoral Aimer Handle

909623

Femoral Aimer Tips

909627 7mm
909628 8mm
909629 9mm
909630 10mm
909631 11mm
909632 12mm

Cannulated Drill Bit

909911 7mm
909913 8mm
909915 9mm
909917 10mm
909919 11mm
909921 12mm

Cannulated End Cutting Reamer

909617 7mm
909618 8mm
909619 9mm
909620 10mm
909621 11mm
909622 12mm

ACL/PCL Sterilization Case

909899

Arthrotek is a registered trademark of Arthrotek, Inc.

Developed in conjunction with Timothy Deakon, M.D., Oakville, Ontario

This brochure is presented to demonstrate the surgical technique utilized by Timothy Deakon, M.D. Arthrotek, as the manufacturer of this device, does not practice medicine and does not recommend this or any other surgical technique for use on a specific patient. The surgeon who performs any procedure is responsible for determining and utilizing the appropriate techniques for such procedure for each individual patient. Arthrotek is not responsible for selection of the appropriate surgical technique to be utilized for an individual patient.

ARTHROTEK[®]
A BIOMET COMPANY

P.O. Box 587, Warsaw, IN 46581-0587 • 574.267.6639 • ©2003 Arthrotek, Inc. All Rights Reserved
web site: www.arthrotek.com • Domestic eMail: arthrotek@arthrotek.com • International eMail: arthrotekeurope@arthrotek.com
Form No. Y-BMT-834/101503/K